

Laparoscopic Cholecystectomy for Acute Cholecystitis in Situs Inversus Totalis: An Extraordinary Approach

Mehmet Tolga Kafadar¹, Metin Yalcin¹, Yildiray Daduk¹, Murat Soyalp², Mehmet Ali Gok¹

¹Clinic of General Surgery, Health Sciences University Mehmet Akif Inan Training and Research Hospital, Sanliurfa, Turkey

²Clinic of General Surgery, Beypazari State Hospital, Ankara, Turkey

Cite this article as: Kafadar MT, Yalcin M, Daduk Y, Soyalp M, Gok MA. Laparoscopic Cholecystectomy for Acute Cholecystitis in Situs Inversus Totalis: An Extraordinary Approach. Eurasian J Emerg Med. 2018; 17: 82-4.

Abstract

Acute cholecystitis with situs inversus totalis is a rare condition. Recently, laparoscopic cholecystectomy is the most preferred method for cholecystitis treatment. Surgeries must be performed with care due to the change in positions of organs and possible anomalies during the operations. It is beneficial to take some technical measures to avoid complications. Here, we present a case of acute cholecystitis with situs inversus totalis and its treatment with emergency laparoscopic cholecystectomy.

Keywords: Situs inversus, left-sided gallbladder, cholecystitis, emergency laparoscopic cholecystectomy

Introduction

Situs inversus totalis (SIT) is a congenital condition with an autosomal pattern of inheritance. It has the form of mirror image in abdomen that presents symmetrical placement; there is no organ dysfunction in this clinical case. Its incidence is between 1/5000 and 1/10000 worldwide. Even such patient has liability to anomaly it is not like the affinity to cholecystitis (1). Some technical difficulties may arise during surgery performed on patients with both SIT and cholecystitis (2). Here we present a case wherein laparoscopic cholecystectomy was successfully performed in a 59-year-old female diagnosed with acute cholecystitis and SIT.

Case Presentation

A 59-year-old female was admitted to our clinic with complaints of severe abdominal pain, nausea, and vomiting for 2 days. Based on her history, it was clear that she had pain in the epigastric region that spread toward the upper-left quadrant after meals from time to time for the previous 3 months. Her past history was not notable for any disease. During physical examinations of the epigastric region, sensitivity and defense were determined. Auscultation was taken from cardiac apex beat nipple. Laboratory examinations revealed the following: White Blood Cell: 12600/mm³,

C-Reactive Protein: 20 mg/L, Aspartate aminotransferase: 55 U/L, and Alanine transaminase: 60 U/L. Other parameters were normal. On posterior–anterior chest radiography, heart shadow and fundus flatulence were observed on the right side (Figure 1a). On abdominal tomography, SIT was observed (Figure 1b), and in the gall bladder lumen, multiple millimetric stones were observed. With the existing symptoms, emergency laparoscopic cholecystectomy was scheduled for the patient. During the surgery, the surgeon was on the right side of the patient across the assistant and camera. The abdomen was insufflated using a veres needle through a 1-cm incision on the navel. The camera was placed in the abdomen using a 10-mm trocar. Gall bladder was observed to be hydroptic; its wall was thick and minimally attached to the surrounding tissues (Figure 2). Another 10 mm trocar was placed through the lower xiphoid and upper navel median line. Two units of 5 mm trocar were placed on the left side for mirror symmetry image with the opposite of classical laparoscopic cholecystectomy. The gall bladder was suspended and the dissection was performed. Cystic artery and ductus were found, and cut through with putting hemoclips. The cholecystectomy was completed through separating gallbladder from the liver bed in a retrograde direction. In the bladder, there were multiple millimetric stones. The patient was discharged with full recovery 2 days later. Informed consent was obtained from the patient.



Corresponding Author: Mehmet Tolga Kafadar e-mail: drtolgakafadar@hotmail.com

Received: 17.04.2017 • **Accepted:** 25.04.2017 • **Available Online Date:** 09.08.2017

©Copyright 2018 by Emergency Physicians Association of Turkey - Available online at www.eajem.com

DOI: 10.5152/eajem.2017.82473

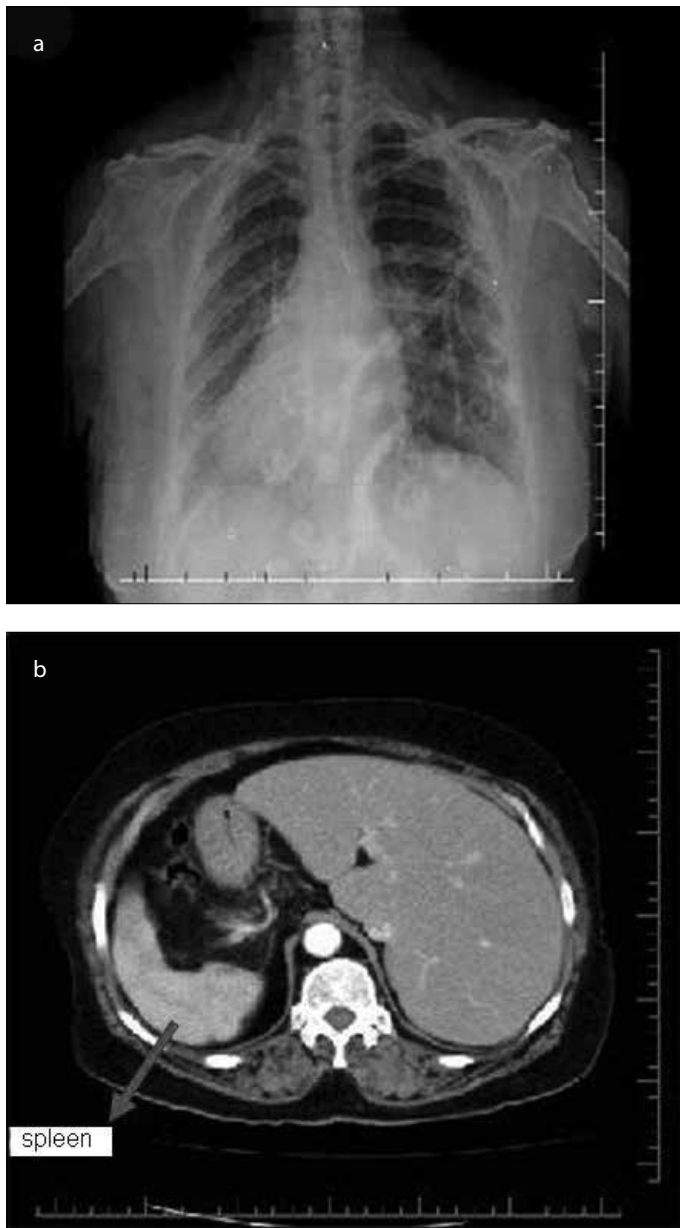


Figure 1. a, b. Posterior–anterior chest X-ray (a) and abdominal tomography (b) image of the patient

Discussion

Situs inversus is a rare genetic embryologic anomaly. Eventhough, this anomaly may only be thoracic or abdominal (partial situs inversus), it may be also related with both spaces together (SIT). In SIT, all thoracic and abdominal visceral organs are symmetrical to the middle line of required location (3). Campos (4) performed the first laparoscopy in SIT cases in 1991. Han et al. (5) performed a single-incision multiport in 2011. In contrast to general laparoscopy, the location of the monitor and general surgeon will be on the opposite side in SIT cases. The trocar entrance places should be arranged by considering the new locations. However, difficulties are experienced by left-handed surgeons in normal cases are also experienced by right-handed surgeon in these cases. Due to difficulties in the use of surgical instruments, it is

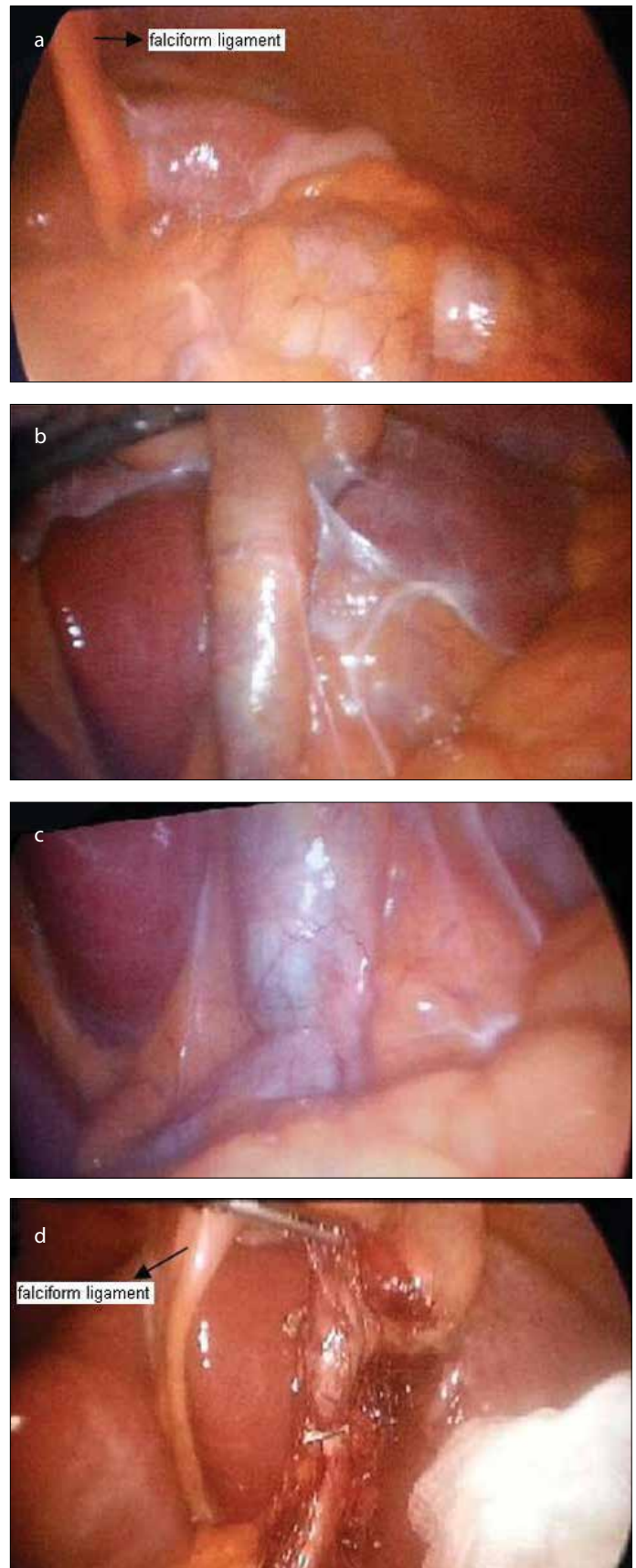


Figure 2. a-d. Left-sided edematous gallbladder image at the exploration

possible to experience some difficulties in manipulation and increasing complications (2). Hence, related different methods are defined. Machado and Chopra (6) examined 26 patients with SIT and suggested that laparoscopic cholecystectomy can be safely performed in these patients.

Situs inversus totalis may be observed together with bronchitis, sinusitis, congenital heart diseases, and biliary atresia. The incidences of extrahepatic biliary, venous, and arterial anomalies in SIT patients have the same incidence as those in the general population. However partial situs inversus cases have lower incidence. The biliary tract and vascular anomalies may have greater incidence in partial situs inversus cases. Therefore, it is recommended that intraoperative cholangiography or switch to open surgery should be performed in partial situs inversus cases, if required (1). Torretta et al. (7) stated that open surgeries are safer in such cases.

There is no increase of acute cholecystitis determined for the patients with situs inversus in literature. However, these patients may have some difficulties in the diagnosis period. Generally, pain at the epigastric region or upper-left quadrant is experienced. The pain can spread toward the left shoulder or lower scapula. Even the gall bladder is localized on the left side and 10% of the patients may have pain in the right side of the abdomen (8). Our patient experienced pain in the epigastric region, which spread toward the left side. Early diagnosis can be achieved through chest X-ray and electrocardiography for identification of dextrocardia or through direct abdominal X-ray for identification of right positioned flatulence. It is possible to identify organ transposition through abdominal ultrasonography, thorax, and abdominal tomography (9).

The situs inversus patients with cholecystitis may have longer operation time due to difficulties in orientation and adaptation for laparoscopic cholecystectomy. The surgeon who uses left hand has the advantage for adaptation during surgery (10). In our case, the surgeons were right-handed and the operation lasted 60 min. If there is no anomaly, including the cystic duct or main bile duct, then laparoscopic cholecystectomy can be applied as a secure and easy method for the patients with situs inversus. If it is clinically required, cholangiography and endoscopic retrograde cholangiopancreatography should be applied.

Conclusion

By requiring a certain level of experience, laparoscopic cholecystectomy can be safely performed in patients with situs

inversus and symptomatic cholelithiasis. It should be considered that sometimes anatomic variations may be seen more often than normal cholecystectomy cases. It should not be spare for switching to open surgery if it is required.

Informed Consent: Written informed consent was obtained from patient who participated in this case.

Peer-review: Externally peer-reviewed.

Author Contributions: Concept – M.T.K.; Design – M.T.K., M.A.G.; Supervision – M.T.K.; Resources – M.T.K., M.Y., Y.D., M.S.; Materials – M.T.K., M.Y., Y.D., M.S.; Data Collection and/or Processing – M.T.K., M.Y., Y.D., M.S.; Analysis and/or Interpretation – M.T.K., M.A.G.; Literature Search – M.T.K.; Writing Manuscript – M.T.K.; Critical Review – M.T.K., M.A.G.

Conflict of Interest: The authors have no conflict of interest to declare.

Financial Disclosure: The authors declared that this study has received no financial support.

References

1. Yaghan R, Gharaibeh K, Hammori S. Feasibility of laparoscopic cholecystectomy in situs inversus. *J Laparoendosc Adv Surg Tech*. 2001; 11: 233-7. [\[CrossRef\]](#)
2. Alsabek MB, Arafat S, Aldirani A. A case report of laparoscopic cholecystectomy in situs inversus totalis: Technique and anatomical variation. *Int J Surg Case Rep*. 2016; 28: 124-6. [\[CrossRef\]](#)
3. Puglisi F, Troilo VL, De Fazio M, Capuano P, Lograno G, Catalano G, et al. Cholecystectomy in situs visereum inversus totalis. Does laparoscopy increase the pitalls? *Chir Ital*. 2006; 58: 179-83.
4. Campos L, Sipes E. Laparoscopic cholecystectomy in 39-year-old female with situs inversus. *J Laparoendosc Surg*. 1991; 1: 123-5. [\[CrossRef\]](#)
5. Han HJ, Choi SB, Kim CY, Kim WB, Song TJ, Choi SY. Single-incision multiport laparoscopic cholecystectomy for a patient with situs inversus totalis: report of a case. *Surg Today*. 2011; 41: 877-80. [\[CrossRef\]](#)
6. Machado NO, Chopra P. Laparoscopic cholecystectomy in a patient with situs inversus totalis: feasibility and technical difficulties. *JSL*. 2006; 10: 386-91.
7. Torretta A, Zeri K, Mascagni D. Traditional cholecystectomy in a patient with situs viscerum inversus partialis. *G Chir*. 1999; 20: 293-5.
8. Mn R, S MS, Bb SK. Laparoscopic cholecystectomy in situs inversus totalis. *J Clin Diagn Res*. 2014; 8: ND03-5.
9. Shah A, Patel B, Panchal B. Laparoscopic cholecystectomy in a patient with situs inversus. *J Minim Access Surg*. 2006; 2: 27-8. [\[CrossRef\]](#)
10. Salama IA, Abdullah MH, Houseni M. Laparoscopic cholecystectomy in situs inversus totalis: Feasibility and review of literature. *Int J Surg Case Rep*. 2013; 4: 711-5. [\[CrossRef\]](#)